

**CASE REPORT**

**Evaluation and treatment decision strategies  
for nerve lesions-in-continuity using the  
Checkpoint nerve stimulator**

**Michael Hausman, MD**

Vice-Chairman, Department of Orthopedic Surgery  
Chief, Upper Extremity Surgery,  
Mount Sinai Health System

# Evaluation and treatment decision strategies for nerve lesions-in-continuity using the Checkpoint nerve stimulator

Michael Hausman, MD

The treatment of peripheral nerve injuries caused by stretching, crushing or non-transecting penetrating trauma remains a major challenge. The decision whether to perform a neurolysis or proceed to nerve resection and grafting or nerve transfer is challenging, especially in the case of a neuroma-in-continuity with a complete palsy by physical exam.

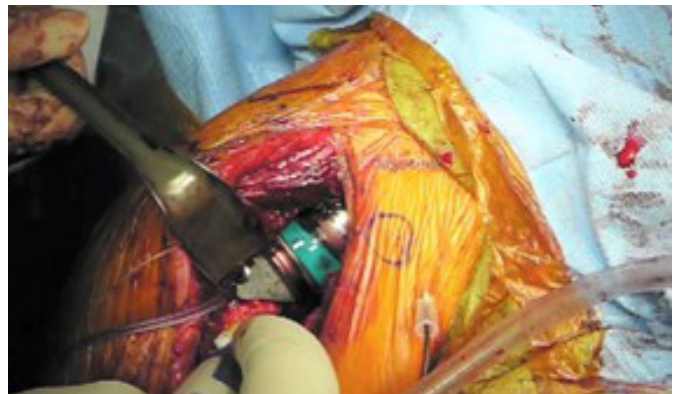In such cases, imaging studies, such as MR or ultrasound cannot provide clarity on the best approach. Electrophysiological testing would, hypothetically, be helpful, but more often than not, the conclusion is that there is a severe nerve injury with fasciculation, indicating axonal injury, and no voluntary muscle response. In other words, it confirms that the nerve isn't working but does little to clarify the decision of neurolysis versus reconstruction with graft or transfer.

Intraoperative assessment with a reliable nerve stimulator, providing a variable, reproducible stimulus, can be of help in assessing the function of a motor nerve. Direct, intraoperative stimulation and assessment by the surgeon can add important and useful information, particularly because the surgeon is looking directly at and has the ability to touch the nerve, thus eliminating thick layers of intervening tissue, inference and the inherent problem of a poor signal-to-noise ratio that compromises conventional electrophysiological information.

For instance, we know from experience that direct surface stimulation of a peripheral nerve with a physiologic, biphasic stimulus of 0.5 mA and a pulse width of 25-50 microseconds produces a vigorous and unambiguous muscle contraction. The lack of

response to stimulus in this range indicates some degree of nerve dysfunction, which may be subtle. An example is axillary nerve dysfunction after trauma or a failed previous surgery. If the surgeon plans a revision procedure to a reverse total shoulder prosthesis, which is dependent upon a healthy, strong deltoid, confirming axillary nerve normal function would be important.

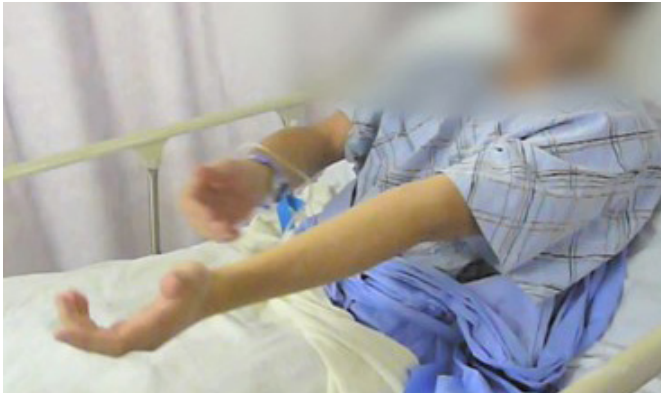It is our practice to routinely use the Checkpoint® stimulator to identify and check the axillary nerve. If 0.5 mA does not produce a strong contraction, we perform an external neurolysis and test again. Consistently, in the absence of a more serious injury to the nerve, incising or stripping the thickened epineurium improves the function and a strong contraction in the 0.5 mA range is achieved.



**Figure 1. In this rTSA, the Checkpoint stimulator is used to check the axillary nerve after placing the trial components. The “threshold stimulus” should not increase and, if it does so, overstretching of the axillary nerve must be suspected.**



Scan QR code to view video.



**Figure 2. This patient suffered damage to the musculoskeletal nerve after a Latarjet procedure with inability to flex the elbow.**

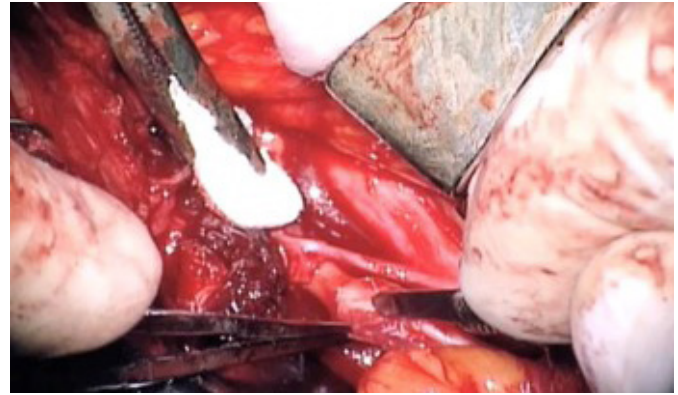


Scan code to view video

Similarly, it is important to prevent overstretching the nerve, especially as rTSA is dependent upon some degree of stretch for stability (Figure 1). To assess this, we establish the “threshold stimulus”, which is the lowest stimulus intensity required to produce any deltoid response. This is determined by placing the stimulator in the 0.5 mA range and gradually increasing the pulse width with the slide switch until a muscle twitch is observed. This is marked, on the stimulator, as the “threshold stimulus”. The test is repeated after inserting the trial components. If the threshold is increased (meaning a stronger stimulus is needed to produce a muscle response), then the nerve is being stretched and the components should be downsized and stability and nerve function reassessed.

Intraoperative nerve testing with the Checkpoint stimulator is also helpful with more serious nerve injuries. For example, this 22-year-old underwent a Latarjet procedure for recurrent shoulder instability and awoke from anesthesia with inability to flex his elbow and a complete, isolated musculoskeletal nerve injury. (Figure 2) Electrodiagnostic studies showed no distal conduction in the distribution of the musculoskeletal nerve and fibrillations in the brachialis and biceps muscles.

During surgical exploration of the brachial plexus, a neuroma-in-continuity was found in the musculoskeletal nerve (Figure 3) with a discrete area of thickening and scarring. Testing proximal to the lesion produced no response, even in the stronger,

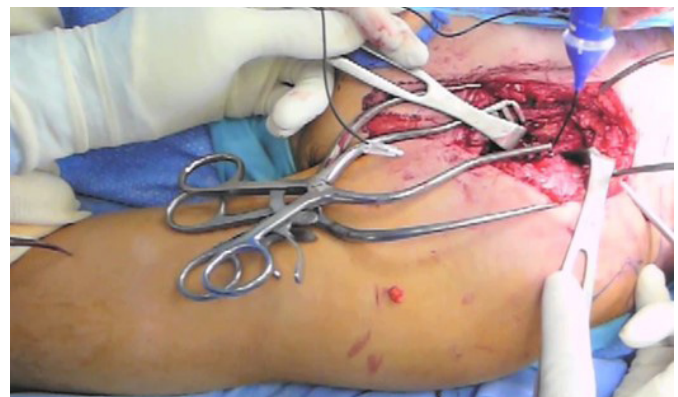

**Figure 3. The damaged area of the musculoskeletal nerve is dissected under the operating microscope. Some fascicles are densely scarred and unresponsive, but others can be traced and dissected across the area of damage.**

2.0 mA range. Accordingly, the operating microscope was used to perform an internal neurolysis. Damage to multiple fascicular groups was seen, but some fascicles could be traced through the scarred area. After dissection, the nerve was stimulated again proximal to the



lesion and a response could be observed in the elbow flexors in the 2.0 mA range. From this finding, we can infer that the patient will recover at least antigravity elbow flexion and that neurolysis, rather than grafting or Oberlin transfer, is indicated. After further dissection, the nerve is tested again and a



**Figure 4. The nerve response is tested at 2.0 mA and then again at 0.5 mA. In this patient, the good contraction observed at 2 mA indicates that there will be at least partial recovery, while the weak response at 0.5 mA indicates near complete recovery will occur.**

very weak, but unambiguous twitch is seen in the brachialis in the 0.5 mA range. The presence of any response in the 0.5 mA range implies that the patient will have a complete recovery, which, in this case, was complete by 6 weeks after surgery.

Thus, intraoperative nerve testing can help with the nerve reconstruction decision tree by applying the “Rule of 2”. While not validated with a rigorously performed study, there is an evolving consensus that with lesions-in-continuity, a distal response in the 2.0 mA range indicates that with neurolysis, recovery will occur at, at least, motor grade III level and, therefore, neurolysis is warranted. A response in the 0.5 mA range implies that complete recovery is likely, while failure to observe any response in the 2.0 mA and maximum pulse width range implies that the nerve is sufficiently damaged that no recovery will occur and that grafting or nerve transfer should be performed.



## About the author

**Michael Hausman, MD**, is Vice-Chairman Dept. of Orthopedic Surgery, Chief, Upper Extremity Surgery, Mount Sinai Health System, New York.

---

The Checkpoint Stimulator is a single-use, sterile device intended to provide electrical stimulation of exposed motor nerves or muscle tissue to locate and identify nerves and to test nerve and muscle excitability. Do not use this Stimulator when paralyzing anesthetic agents are in effect, as an absent or inconsistent response to stimulation may result in inaccurate assessment of nerve and muscle function. For a complete list of warnings and precautions regarding the use of the Stimulator please see [www.checkpointsurgical.com](http://www.checkpointsurgical.com).

Note: Case Reports are company funded and non-peer reviewed.

