CASE REPORT

Protection of the facial nerve in temporomandibular joint reconstruction surgery using the Checkpoint nerve stimulator

Mehmet Ali Altay, DDS, PhD; Dale A. Baur, DDS; and Faisal A. Quereshy, MD, DDS, FACS

Background

The ability to preserve the functional integrity of the facial nerve is a critical measure of success in temporomandibular joint (TMJ) surgery.[1] Despite the care taken during surgical interventions as well as surgeon's skill in the approach to the TMJ, the facial nerve is always at risk and it is difficult to provide adequate exposure without causing injury.[2] A possible injury which may result in both functional and cosmetic deficits constitutes a relevant and distressing complication of TMJ surgery.[1]

The incisions that provide access to the TMJ are established in accordance with the requirements of the anatomical region and its function.[3] However, facial nerve injuries resulting from TMJ surgery are still encountered with an incidence ranging from 1% to 32%.[2] In their recent study, Hohman et al. evaluated procedure specific incidence and risk factors in patients with iatrogenic facial nerve injury and concluded that the most common operation resulting in facial nerve injury was TMJ replacement.[4]

Numerous incisions for approaching TMJ have been proposed. The preauricular approach is considered in the literature to be a relatively safe procedure despite its less favorable cosmetic outcomes and is commonly performed with a submandibular "Risdon's incision" for TMJ replacement procedures. In this report our aim is to present protection of the facial nerve with the Checkpoint® nerve stimulator (Checkpoint Surgical, Cleveland, OH) in a bilateral TMJ replacement surgery comprising of preauricular and Risdon's incisions.

Case report

An 18-year-old male patient with congenital bilateral condylar deformities was operated on for reconstruction of the mandibular condylar segments with costochondral bone grafts.

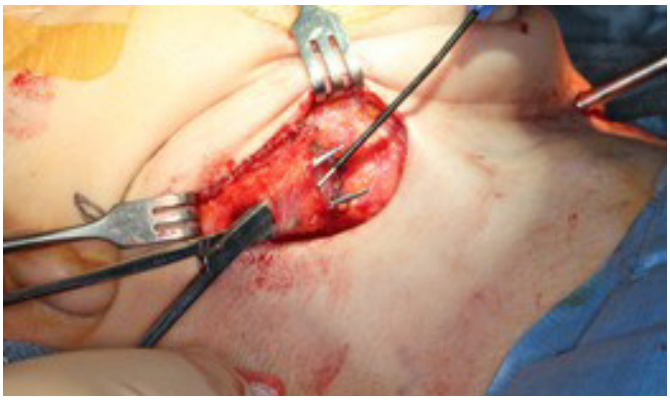

Initial submandibular Risdon's incisions were performed bilaterally on the skin and continued down to subcutaneous tissue exposing the platysma muscle. Further incisions were then carried out exposing the superficial layer of the deep cervical fascia.

With the aid of the Checkpoint nerve stimulator, dissection was carried down to the superficial layer of deep cervical fascia. Pockets were made by passing down the submandibular glands going superior to the inferior border of the mandible as the body and the angle of the mandible were exposed.

Preauricular incisions were made through skin and subcutaneous tissue exposing the temporalis fascia. Dissection then continued down to the level of the patient's condylar heads.

At this point, nerve monitoring with Checkpoint nerve stimulator was performed once again to avoid injury to the zygomatic and septal branches of the facial nerve. To our experience, Checkpoint biphasic nerve stimulator provided safe and effective monitoring not only for protection of the facial nerve but also to assess its functioning capacity.

Once both condyles were appropriately visualized,

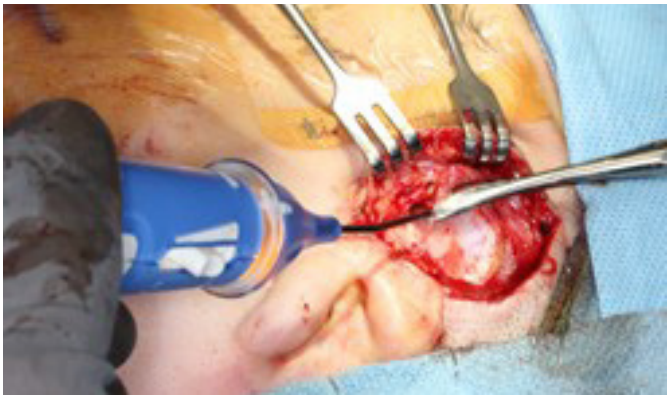

resections were performed removing the condyles as well as the coronoid processes of the mandible after proper dissection of the soft tissues with the aid of Checkpoint nerve stimulator. The device was used with a current level of 2 mA and a pulse width of 100 microseconds which provided repetitive stimulations and consequent muscular contractions without resulting in nerve fatigue. As mentioned in previous studies, higher amplitude settings and an adjustable pulse width may be of further benefit and render the device exclusively useful when operating on dense or fibrous tissues. However it should also be kept in mind that the stimulator should not be utilized when paralyzing anesthetic agents are effective, as inaccurate assessment of nerve and muscle function may be encountered.

Following the harvest of costochondral grafts, temporomandibular joints were successfully reconstructed with autogenous bone and an uneventful healing with natural function of the facial nerve was observed. We believe that atypical surgical anatomy of the patient in the presented case could complicate the procedure and result in facial nerve injury if proper nerve monitoring was not utilized. Checkpoint stimulator provided us with dependable monitoring, which enabled comfortable dissections and a successful surgical outcome.

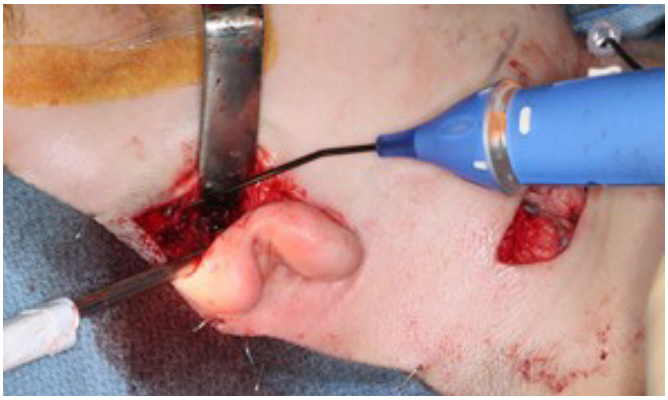

References

1. Weinberg S, Kryshtalskyj B. 1992. Facial nerve function following temporomandibular joint surgery using the preauricular approach. J Oral Maxillofac Surg. 50(10):1048-51.
2. do Egito Vasconcelos BC, Bessa-Nogueira RV, da Silva LC. 2007. Prospective study of facial nerve function after surgical procedures for the treatment of temporomandibular pathology.J Oral Maxillofac Surg. 65(5):972-8.
3. Nogueira RV, Vasconcelos BC. 2007. Facial nerve injury following surgery for the treatment of ankylosis of the temporomandibular joint. Med Oral Patol Oral Cir Bucal. 1;12(2):E160-5.
4. Hohman MH, Bhama PK, Hadlock TA. 2014. Epidemiology of iatrogenic facial nerve injury: a decade of experience. Laryngoscope.124(1):260-5.

Mehmet Ali Altay, DDS, PhD, is Doctor of Oral and Maxillofacial Surgery at Akdeniz University, Faculty of Dentistry, Antalya, Turkey. He is currently a research fellow at Case Western Reserve University, School of Dental Medicine, Department of Oral and Maxillofacial Surgery.

Dale A. Baur, DDS, is an Associate Professor and Chair of Oral and Maxillofacial Surgery at Case Western, Reserve University, School of Dental Medicine, Department of Oral and Maxillofacial Surgery.

Faisal A. Quereshy, MD, DDS, FACS, is an Associate Professor and Residency Program Director at Case Western Reserve University, School of Dental Medicine, Department of Oral and Maxillofacial Surgery.
