PROTECTION OF THE MARGINAL MANDIBULAR BRANCH OF THE FACIAL NERVE IN MANDIBULAR RESECTION USING THE CHECKPOINT BIPHASIC HANDHELD NERVE STIMULATOR

Dale Baur, DDS
Case Western Reserve University
Chair Department of Oral and Maxillofacial Surgery,
School of Dental Medicine
Chief of Oral and Maxillofacial Surgery
Case Western Reserve University Hospital

This case involves resection of a large benign mandibular tumor requiring a combined intra and extra-oral approach for access. After dissection through the skin, subcutaneous tissue, and platysma muscle, the superficial layer of the deep cervical fascia is encountered. The Checkpoint Stimulator/Locator is used to help monitor the location of the marginal mandibular branch of the facial nerve as we dissect through this layer.

The Checkpoint is used to test the tissue to be dissected while monitoring the ipsilateral lower lip and corner of the mouth for motor activity to make certain the marginal mandibular branch of the facial nerve is avoided and inadvertently damaged.

Because Checkpoint uses biphasic, alternating current output, its sterile probe end can be passed/wanded over the region of dissection to assure that no motor activity is generated. I typically select an amplitude of 2mA and a moderate pulse width of approximately 100 microseconds when using the Checkpoint device; higher levels of stimulation are possible and may be particularly helpful when locating a nerve through dense or fibrous tissue such as those encountered in radiated or previously-operated tissues.

Compared to other devices I've used, the Checkpoint device appears to offer a more definitive response that is easier to read. Prior to our use of the Checkpoint device it has been difficult, especially in cases that involve

dissection through densely fibrous tissue, to identify anatomic landmarks and determine where the dissection is advancing within three-dimensional space. Reliable motor feedback from the nerve stimulator in these cases is imperative.

When having previously used a conventional direct-current stimulator in parotidectomy procedures, after the nerve has been contacted 1 to 2 times we have commonly experienced that it becomes non-responsive to stimulation. Until a period of recovery has occurred, the DC stimulator is not able to provide surgical guidance. When using the Checkpoint device we have not experienced non-responsiveness of the nerve even following repeated applications of energy to the nerve. In addition, we find the motor response to Checkpoint's biphasic stimulation is reliable intra-operatively since the Checkpoint device is capable of delivering a tetanic contraction versus the simple muscle twitch response to DC stimulus.

The visual cues from the light at the tip of the handle are helpful in determining first, that the device is operational and properly grounded to complete the circuit and second, to indicate that tissue is being actively stimulated. A red light indicates that stimulation is not possible due to improper placement of the grounding needle electrode or due to the high tissue impedance that may be encountered in less conductive tissue such as dense scar. A yellow light indicates that the system is ready and capable of delivering stimulation and a flashing yellow light indicates the active delivery of stimulation to the targeted tissue. The single-use sterile device remains active for up to 7 hours.

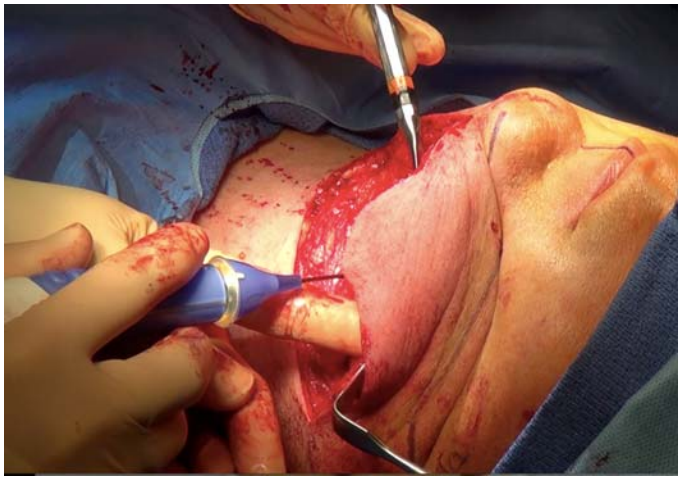

Upon our surgical approach to the inferior border of the mandible, we were able to demonstrate depression of the lower lip due to contraction of the musculature innervated by the marginal mandibular branch of the facial nerve. At this point we can be assured that the nerve is intact and that we have kept it out of harm's way during our soft-tissue dissection, allowing us to proceed to the boney aspect of the surgery involved in the remainder of the case without concern for iatrogenic injury to the nerve.

See www.checkpointsurgical.com for indications, contraindications, precautions and warnings.