

Checkpoint Stimulator Use in Melanoma Lymph Node Surgery



Stanley P. Leong, MD
Chief of Cutaneous Oncology
California Pacific Medical Center and Research Institute
Emeritus Professor of Surgery
University of California San Francisco

Worldwide incidence of melanoma is rising.[1] Sentinel lymph node biopsy (SLNB) is indicated for patients with primary melanoma with T1b lesions and beyond [2] based on the recent classifications of the 8th edition of the American Joint Committee on Cancer (AJCC).[3] The status of the SLN has been shown to be the strongest predictor of melanoma-specific survival by the MSLT-I.[4] Although MSLT-II has shown again that SLN status is a strong predictor of melanoma-specific survival, the therapeutic benefit of completion lymph node dissection (CLND) has not been demonstrated. Thus, in patients with low tumor burden in the SLN(s), CLND may not be necessary.[5] SLNB is a less morbid procedure with complication rate of about 5% [6] when compared with CLND of as high as over 50%.[7]

Despite the fact that the complications such as lymphedema, pain, and nerve injury from SLNB are much less than those from CLND, major nerves are still exposed during SLNB for different nodal basins. Specific examples are: the spinal accessory nerve in the posterior triangle of the neck; thoracodorsal and long thoracic nerve in the axilla; ulnar, median, and radial nerves in the deep epitrochlear basin; femoral nerve in the groin; and sciatic nerve in the popliteal fossa. During lymph node dissection in these nodal basins, it is critical to identify and carefully preserve these nerves. Due to the more limited operative field in SLNB, the nerves may be more difficult to identify in these nodal basins. Whether undertaking a SLNB or CLND, it is imperative to identify and monitor the nerve so that it will be carefully preserved during dissection.

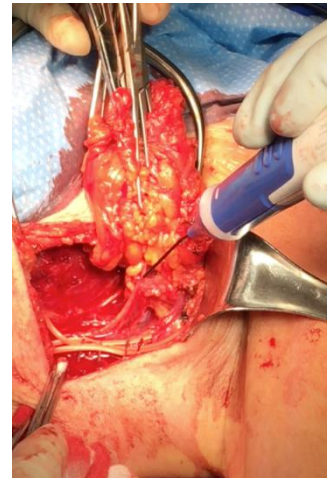


Figure 1: Left Axillary Node Dissection.

Due to its variable stimulation parameters, the Checkpoint Stimulator has proven to be an excellent tool to assist in localizing these nerves prior to visualization. The use of a charge-balanced, biphasic stimulation waveform allows safe continuous stimulation to tissue without causing any diminished muscle response or risk of nerve injury over time. This ability to repeatedly stimulate enables me to repeatedly confirm nerve function, thus, enabling me to preserve the nerve throughout the procedure, which can be especially helpful during difficult dissections.

The two linked videos provide a brief demonstration of my usage of Checkpoint Stimulator in two recent lymph node dissections. The first case was an axillary lymph node dissection (Figure 1), showing the identification of the thoracodorsal nerve with the contraction of latissimus dorsi, and the long thoracic nerve with the contraction of the serratus anterior respectively. Initially, I used the 2.0 mA setting and swept across the tissue. When the stimulator probe was approximately 2-3mm from the nerve, a robust contraction of the muscle was observed. I then reduced the amplitude to



Scan to view
Axillary LND Video

0.5 mA and pinpointed the nerve location. The device also employs a higher frequency setting of 16hz producing a tetanic contraction of muscle as opposed to a single twitch usually associated with nerve stimulation. I believe this nerve locating technique is not only safer, but reduces dissection time. In the second case, the femoral nerve during an inguofemoral lymph node dissection was identified using the Checkpoint Stimulator and the nerve location was confirmed with the contraction of the anterior thigh muscles. In the same way, I started with a higher amplitude setting of 2.0 mA approximating the nerve location to within several millimeters, then confirmed the location at the 0.5 mA setting.



Scan to view Femoral
Nerve Video

In summary, for melanoma lymph node surgery either SLNB or lymph node dissection in the neck, axillary, epitrochlear, inguinal, and popliteal nodal basins, it is my practice that a Checkpoint Stimulator should be always available to confirm the appropriate nerve to avoid injury. In particular, during SLNB, as the operative field is relatively limited, the Checkpoint Stimulator will be of great benefit to identify and confirm the nerve. For the SLNB of the posterior neck and the popliteal fossa, it is critical to identify and confirm the spinal accessory nerve and the sciatic nerve respectively, as the consequence of cutting these nerves is disastrous.

References:

1. Siegel R, Naishadham D, Jemal A. Cancer statistics, 2013. *CA Cancer J Clin.* 2013;63:11–30.
2. Wong SL, Faries MB, Kennedy EB, et al. Sentinel lymph node biopsy and management of regional lymph nodes in melanoma: American Society of Clinical Oncology and Society of Surgical Oncology Clinical Practice Guideline Update. *J Clin Oncol.*2018;36:399–413.
3. Gershenwald JE, Scolyer RA, Hess KR, et al. Melanoma staging: evidence-based changes in the American Joint Committee on Cancer eighth edition cancer staging manual. *CA Cancer J Clin.* 2017;67:472–492.
4. Morton DL, Thompson JF, Cochran AJ, et al. Final trial report of sentinel-node biopsy versus nodal observation in melanoma. *N Engl J Med* 2014;370:599–609.
5. Faries MB, Thompson JF, Cochran AJ et al. Completion dissection or observation for sentinel-node metastasis in melanoma. *N Engl J Med* (2017) 376(23):2211–2222.
6. Wrightson WR, Wong SL, Edwards MJ, Chao C, Reintgen DS, Ross MI, Noyes RD, Viar V, Cerrito PB, McMasters KM. Complications associated with sentinel lymph node biopsy for melanoma. *Ann Surg Oncol* 2003; 10: 676-680
7. de Vries M, Hoekstra HJ, Hoekstra-Weebers JE. Quality of life after axillary or groin sentinel lymph node biopsy, with or without completion lymph node dissection, in patients with cutaneous melanoma. *Ann Surg Oncol* 2009; 16: 2840-2847

The Checkpoint Stimulator is a single-use, sterile device intended to provide electrical stimulation of exposed motor nerves or muscle tissue to locate and identify nerves and to test nerve and muscle excitability. Do not use the Checkpoint Stimulator when paralyzing anesthetic agents are in effect, as an absent or inconsistent response to stimulation may result in inaccurate assessment of nerve and muscle function. For a complete list of warnings and precautions regarding the use of the stimulator please see www.checkpointsurgical.com

Note: White Papers are Company funded and not peer reviewed.